

# The Use of High-Frequency Percussive Ventilation for Whole-Lung Lavage: A Case Report

Sudhakar Kinthala, MD, FNCA,\* Mark Liang, DO,\* Felix Khusid, RRT-ACCS,† and Sebron Harrison, MD‡

Whole-lung lavage (WLL) remains the gold standard in the treatment of pulmonary alveolar proteinosis. However, anesthetic management during WLL can be challenging because of the risk of intraoperative hypoxemia and various cardiorespiratory complications of 1-lung ventilation. Here, we describe a novel strategy involving the application of high-frequency percussive ventilation using a volumetric diffusive respirator (VDR-4) during WLL in a 47-year-old woman with pulmonary alveolar proteinosis. Our observations suggest that high-frequency percussive ventilation is a potentially effective ventilation strategy during WLL that may reduce the risk of hypoxemia and facilitate lavage. (A&A Practice. XXX;XXX:00–00.)

**P**ulmonary alveolar proteinosis (PAP) is a rare disease characterized by the progressive accumulation of lipoproteinaceous material in the alveolar space, leading to impaired gas exchange and respiratory symptoms of variable severity.<sup>1</sup> Whole-lung lavage (WLL) remains the gold standard in the treatment of PAP<sup>2</sup>; however, the anesthetic management of patients undergoing WLL can be challenging. In addition to the complications associated with 1-lung ventilation, patients can experience ventilation/perfusion mismatch with subsequent hypoxemia during instillation of the lavage solution. Here, we describe the novel use of high-frequency percussive ventilation (HFPV) provided by a volumetric diffusive respirator (VDR-4; Percussionaire Corp, Sandpoint, ID) during WLL in a 47-year-old woman with PAP. The patient provided written permission for publication of this case report.

## CASE DESCRIPTION

A 47-year-old woman presented with a 3-month history of progressively worsening dyspnea on exertion that was associated with fever, nonproductive cough, nausea, vomiting, and generalized weakness. Her medical history included chronic obstructive pulmonary disease, for which she had been receiving home oxygen therapy (4 L/min). Her workup for dyspnea included bronchoalveolar lavage, which showed pigment-laden macrophages. Histopathological examination of lung biopsy specimens showed predominantly distended alveoli, filled with thick, proteinaceous fluid, and prominent intra-alveolar accumulation of pink proteinaceous material that stained negative with Congo red and positive with periodic acid-Schiff stain.

The patient was diagnosed with PAP and subsequently scheduled for WLL. Computed tomography showed that the left lung was more severely affected; thus, we performed left-sided WLL first.

Before induction of anesthesia, peripheral oxygen saturation (SpO<sub>2</sub>) was 86% on room air. In addition to standard anesthetic monitoring, the left radial artery was cannulated for continuous blood pressure monitoring and intermittent blood sampling. After oxygen administration for 3 minutes, saturation increased to 95%. Anesthesia was induced with 2 mg/kg propofol and 1 µg/kg fentanyl; endotracheal intubation with a 37F left-sided double-lumen tube (DLT) was facilitated by 0.5 mg/kg rocuronium. Anesthesia was maintained with 1 minimum alveolar concentration of desflurane.

The patient was placed in the supine position with a bolster placed under the right thorax to induce slight left tilt and facilitate left-sided WLL. The right lung was ventilated with a conventional anesthetic ventilator using synchronized intermittent mandatory ventilation with the following settings: tidal volume, 350 mL; respiratory rate, 18 breaths/min; pressure support, 10 cm H<sub>2</sub>O; positive end-expiratory pressure (PEEP), 4 cm H<sub>2</sub>O; and fraction of inspired oxygen, 1.0. The left lung received HFPV provided by a VDR-4 with the following settings: 595/min percussive rate, 16/min convective rate, 10 cm H<sub>2</sub>O oscillatory continuous positive airway pressure (CPAP), and fraction of inspired oxygen, 1.0. A dual-axis swivel adapter was connected to facilitate uninterrupted HFPV with lavage and suctioning (Figure). Left-lung ventilation was interrupted only when the lavage solution was instilled. It was continued during suctioning, as well as in the absence of any solution. Aliquots of approximately 500 mL of warm saline were instilled into the left lung. After the lung was completely submerged, the saline solution was agitated for approximately 3 minutes via the percussive function of the VDR-4 device. The fluid was aspirated with a suction catheter inserted into the left bronchial lumen of the DLT through the dual-axis swivel adapter (Figure; Supplemental Digital Content, Video, <http://links.lww.com/AACR/A183>). When suction ceased removing any fluid, HFPV was continued in an attempt to mobilize intra-alveolar fluids. Subsequent suctioning produced further fluid. The initially suctioned fluid was opaque and pinkish in color, so the lavage cycle was repeated until the effluent was clear. In total, eight 500-mL

VIDEO+

From the Departments of \*Anesthesiology, †Respiratory Therapy, and ‡Cardiothoracic Surgery, New York-Presbyterian Brooklyn Methodist Hospital, Brooklyn, New York.

Accepted for publication March 7, 2018.

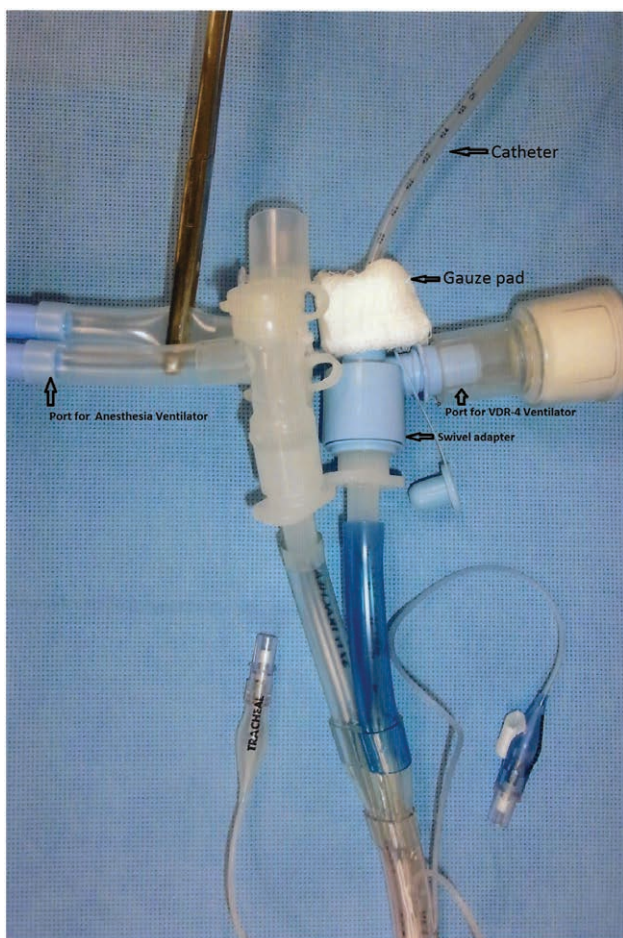
Funding: None.

The authors declare no conflicts of interest.

Supplemental digital content is available for this article. Direct URL citations appear in the printed text and are provided in the HTML and PDF versions of this article on the journal's website ([www.cases-anesthesia-analgesia.org](http://www.cases-anesthesia-analgesia.org)).

Address correspondence to Sudhakar Kinthala, MD, FNCA, Department of Anesthesiology, New York-Presbyterian Brooklyn Methodist Hospital, Brooklyn, NY 11215. Address e-mail to [sudhakarkinthalaresearch@yahoo.co.uk](mailto:sudhakarkinthalaresearch@yahoo.co.uk); [lokakinthala@gmail.com](mailto:lokakinthala@gmail.com).

Copyright © 2018 International Anesthesia Research Society  
DOI: 10.1213/XAA.0000000000000778



**Figure.** Setup of dual-axis swivel adapter to allow uninterrupted ventilation during instillation of fluid and simultaneous use of a suction catheter. A gauze pad was used to prevent leakage of fluid and ventilator gases. VDR indicates volumetric diffusive respirator.

aliquots (total of 4L) of warm saline were instilled into the left lung and 3.2L of fluid were retrieved. Arterial blood gas analysis after 30 minutes of HFPV initiation showed pH of 7.53; arterial partial pressures of carbon dioxide and oxygen, 39 and 285 mm Hg, respectively;  $SpO_2$ , 100%; serum bicarbonate concentration of 33 mmol/L; and base excess, +9 mEq/L.  $SpO_2$  remained between 95% and 100% throughout the procedure. No additional measures were needed to maintain oxygenation or hemodynamics. Once WLL was complete, we performed bronchoscopy to ensure that there was no residual fluid in the airway and that the left lung was mostly clear of proteinaceous material. We removed the endotracheal tube when the patient met the extubation criteria. Afterward, we provided 50% oxygen via a Venturi mask (Hudson RCI, Mexico) to maintain adequate oxygenation. Blood chemistry parameters after WLL were within normal limits.

Although the patient's symptoms had improved 1 day after the procedure, wheezing and cough persisted. Because imaging studies of the right lung showed relevant infiltration, we performed right-sided WLL 6 days after the first procedure. Before induction of anesthesia,  $SpO_2$  was 90% on room air. We followed a similar anesthetic and lavage technique as for the left WLL. The right lung received HFPV

during lavage, while the left was ventilated with a conventional anesthetic ventilator.

The total duration of the procedure was 3 hours. A total of 4.5L of normal saline was instilled into the lung and 3.1L was retrieved by suction.  $SpO_2$  remained between 94% and 100% throughout the procedure. No additional measures were needed to maintain oxygenation or hemodynamics. Because 1.4L of the instilled fluid was not retrieved, and the patient was tachypneic after reversal of the neuromuscular blockade, mechanical ventilatory support (including PEEP 6 cm  $H_2O$  and CPAP 10 cm  $H_2O$ ) was continued for 2 hours. On meeting the extubation criteria, the patient was extubated in the recovery room.

We observed an obvious clinical improvement after the right WLL, and the patient was discharged 5 days after the procedure. Her respiratory function was stable at the 1-, 3-, and 6-month follow-ups.

## DISCUSSION

WLL remains the gold standard in PAP treatment because it provides long-lasting benefits in most patients.<sup>2</sup> The procedure eliminates lipoproteinaceous material from the alveolar space, thereby improving diffusing capacity and oxygenation.<sup>3</sup> Similar to our patient, most patients with PAP scheduled for WLL are hypoxemic at baseline. Moreover, 1-lung ventilation and instillation of large volumes of fluid increase the risk of intraoperative hypoxemia. In this aspect, the patient's position is an important factor and depends on the lung to be lavaged and the preference of the treating team. When the lavaged lung is upward, there is a greater risk of fluid spillage into the dependent lung. Various positional maneuvers used to facilitate lavage and drainage may cause DLT displacement and increase the risk of fluid spillage into the contralateral ventilated lung, thus promoting further ventilation/perfusion mismatch and hypoxemia. During the filling phase, perfusion of the lavaged lung is reduced by compression of the pulmonary vasculature, which tends to reduce the intrapulmonary shunt and increase oxygen saturation. By contrast, during drainage, perfusion of the lavaged lung increases, thus increasing the shunt and resulting in hypoxemia.

Several strategies have been described for managing hypoxemia during WLL, including manual ventilation of partially fluid-filled lungs,<sup>4</sup> intermittent ventilation of both lungs,<sup>5</sup> application of CPAP to the nonventilated lung between lavages,<sup>6</sup> and nitric oxide inhalation.<sup>7</sup> In our patient, we used HFPV to reduce the risk of hypoxemia. HFPV is a form of high-frequency ventilation that delivers very small subtidal volumes at high frequencies. Its unique feature is the presence of a gas-driven piston at the end of the endotracheal tube that functions as a sliding Venturi circuit, thereby acting as both an inspiratory and expiratory valve. Another unique HFPV feature is the passive exhalation of subtidal volumes.<sup>8,9</sup> In addition, HFPV has been shown to improve airway debris and secretion clearance, and to be associated with less barotrauma in patients with inhalational burn injury.<sup>8</sup>

In a prospective study of 35 patients with acute respiratory distress syndrome, HFPV was associated with better oxygenation in patients who did not respond to conventional treatment compared with a historical control.<sup>10</sup> A

retrospective data analysis of 42 patients with moderate and severe acute respiratory distress syndrome showed rapid and sustained improvement in oxygenation and ventilation after HFPV.<sup>11</sup> In a single-center, prospective, randomized controlled trial of 62 burn patients with respiratory failure, HFPV was associated with better oxygenation and ventilation, and with fewer patients requiring rescue ventilation compared with low tidal volume ventilation.<sup>12</sup> In another prospective randomized controlled study of 35 patients with severe burns and inhalation injury, in contrast to conventional ventilation, HFPV improved blood oxygenation during the acute phase, but did not improve mortality.<sup>13</sup>

To the best of our knowledge, this is the first report on the use of HFPV during WLL in a patient with PAP. We did not encounter any hypoxemic episodes during both procedures. This avoided the need for any interventions to treat hypoxemia (eg, recruitment maneuvers or application of high-level PEEP); some of which may have adverse cardiovascular and respiratory effects. The amounts of 4 and 4.5L of lavage fluid we had instilled during left and right WLL, respectively, were well below the average amount of 15.4L (range, 5–40L) and even lower than the lowest amount as reported on the basis of questionnaires from 20 centers in 14 countries practicing WLL,<sup>14</sup> possibly related to better clearance of secretions by HFPV.

In conclusion, our experience suggests that HFPV is a potentially effective strategy for WLL, which may reduce the risk of hypoxemia and facilitate lung lavage. However, it is important that the VDR-4 is operated by an individual who is experienced in its use.<sup>15</sup> ■■

#### DISCLOSURES

**Name:** Sudhakar Kinthala, MD, FNCA.

**Contribution:** This author helped participate in the case management and prepare the manuscript.

**Name:** Mark Liang, DO.

**Contribution:** This author helped participate in the case management and prepare the manuscript.

**Name:** Felix Khusid, RRT-ACCS.

**Contribution:** This author helped participate in the case management and prepare the manuscript.

**Name:** Sebron Harrison, MD.

**Contribution:** This author helped participate in the case management and prepare the manuscript.

**This manuscript was handled by:** Hans-Joachim Priebe, MD, FRCA, FCAI.

#### REFERENCES

1. Ioachimescu OC, Kavuru MS. Pulmonary alveolar proteinosis. *Chron Respir Dis*. 2006;3:149–159.
2. Beccaria M, Luisetti M, Rodi G, et al. Long-term durable benefit after whole lung lavage in pulmonary alveolar proteinosis. *Eur Respir J*. 2004;23:526–531.
3. Trapnell BC, Whitsett JA, Nakata K. Pulmonary alveolar proteinosis. *N Engl J Med*. 2003;349:2527–2539.
4. Aguiar M, Monteiro P, Marques M, et al. Whole lung lavage: report of four cases of alveolar proteinosis. *Rev Port Pneumol*. 2009;15:77–88.
5. Stephen TW, Evans JA. Anaesthesia for serial whole-lung lavage in a patient with severe pulmonary alveolar proteinosis: a case report. *J Med Case Rep*. 2008;2:360.
6. El-Dawlatly A, Hajjar W, Alnassar S, Alsafar R, Abodonya A. Continuous positive airway pressure ventilation during whole lung lavage for treatment of alveolar proteinosis: a case report and review of literature. *Saudi J Anaesth*. 2011;5:76–78.
7. Bingisser R, Kaplan V, Zollinger A, Russi EW. Whole-lung lavage in alveolar proteinosis by a modified lavage technique. *Chest*. 1998;113:1718–1719.
8. Salim A, Martin M. High-frequency percussive ventilation. *Crit Care Med*. 2005;33:S241–S245.
9. Salim A, Miller K, Dangleben D, Cipolle M, Pasquale M. High-frequency percussive ventilation: an alternative mode of ventilation for head-injured patients with adult respiratory distress syndrome. *J Trauma*. 2004;57:542–546.
10. Lucangelo U, Zin WA, Fontanesi L, et al. Early short-term application of high-frequency percussive ventilation improves gas exchange in hypoxemic patients. *Respiration*. 2012;84:369–376.
11. Herbert S, Marianne B, Marc D, Viola VG, Duc NN, Patrick MH. High-frequency percussive ventilation in severe acute respiratory distress syndrome: a single center experience. *J Anaesthesiol Clin Pharmacol*. 2014;30:65–70.
12. Chung KK, Wolf SE, Renz EM, et al. High-frequency percussive ventilation and low tidal volume ventilation in burns: a randomized controlled trial. *Crit Care Med*. 2010;38:1970–1977.
13. Reper P, Wibaux O, Van Laeke P, Vandeenen D, Duinslaeger L, Vanderkelen A. High frequency percussive ventilation and conventional ventilation after smoke inhalation: a randomised study. *Burns*. 2002;28:503–508.
14. Campo I, Luisetti M, Griese M, et al; WLL International Study Group. Whole lung lavage therapy for pulmonary alveolar proteinosis: a global survey of current practices and procedures. *Orphanet J Rare Dis*. 2016;11:497–499.
15. Kunugiyama SK, Schulman CS. High-frequency percussive ventilation using the VDR-4 ventilator: an effective strategy for patients with refractory hypoxemia. *AACN Adv Crit Care*. 2012;23:370–380.